

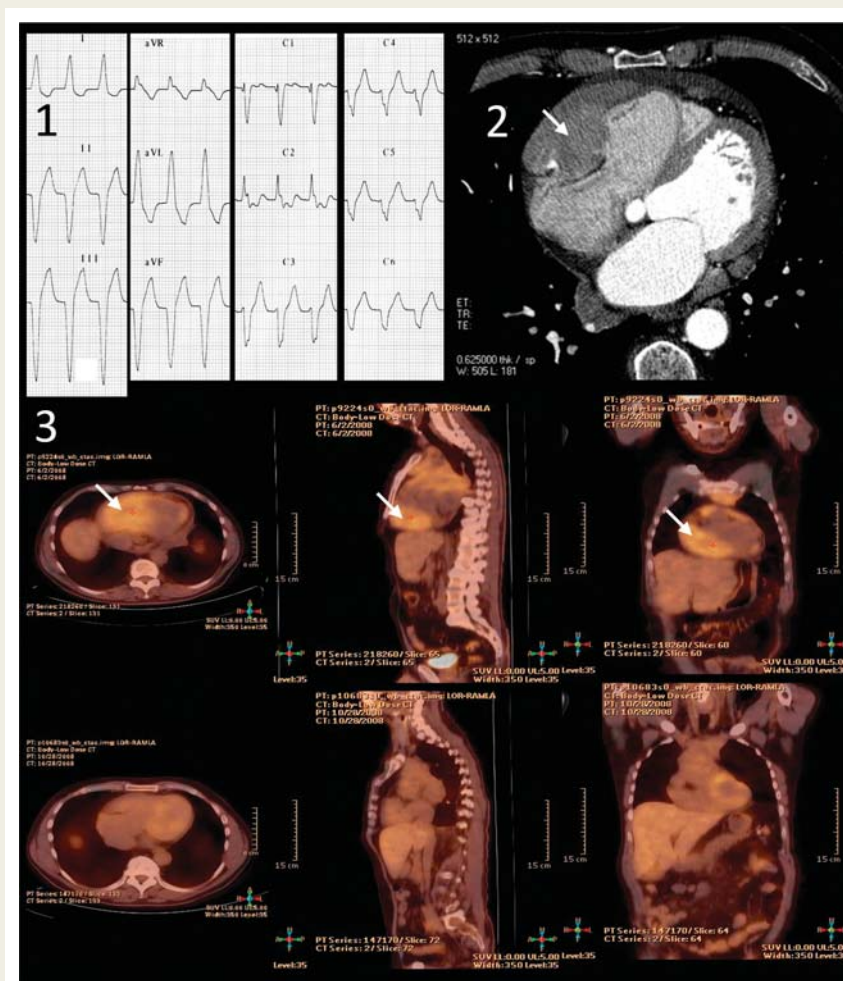
# Ventricular tachycardia reveals cardiac infiltration due to mediastinal lymphoma

Vincent Algalarrondo\*, Srimanta C. Misra, Soumia L. Bennani, Mylene Mabile, Françoise Cavailloles, David Machover, and Michel S. Slama

Thoracic Department, Antoine Bécélère Hospital, 157 Av de la Porte de Trivaux, 92140 Clamart, France

\*Corresponding author. Tel: +33 684440922, Email: vincent.algalarrondo@abc.aphp.fr

A 61-year-old man was referred to us for palpitations and ventricular tachycardia. After being treated by chemotherapy for a mediastinum lymphoplasmocytic lymphoma, a ventricular tachycardia (VT) occurred. It was well tolerated. Several imaging techniques showed that this VT was related to a tumoural infiltration of the anterior part of the right ventricle by the lymphoma. Ventricular arrhythmias were controlled under antiarrhythmic drugs and chemotherapy was continued, with close cardiac follow-up. Complete remission was reached with restoration of a normal right ventricular function and resolution of the ventricular arrhythmias.



**Figure 1** Part 1: Twelve lead ECG during tachycardia shows left bundle branch block morphology with superior axis. Note also the unusual aspect in leads V1-V3 which was confirmed in all the patient's ECGs and may be explained, at least in part, by the size of the tumor and the major RV infiltration. Part 2: CT scan, mediastinum window shows the tumoral infiltration of the anterior wall of the right ventricle (arrow). Part 3: [(18)F]Fluorodeoxyglucose positron emission tomography. In the upper row, three views of the thoracic area before chemotherapy show an abnormal uptake by the cardiac tumor (arrow). The lower part of the figure displays the same views five months after chemotherapy, illustrating the complete disappearance of tumoral uptake after treatment.

## Case report

A 61-year-old man was referred in the intensive care unit (ICU) from an oncology department for palpitations and a wide complex tachycardia on surface electrocardiogram (ECG).

He had been diagnosed with mediastinal lymphoplasmocytic lymphoma 2 years before (2006). At first, he refused any kind of treatment. In June 2008, he considered chemotherapy. Then, he was treated with rituximab. A modified DHAP protocol consisting of oxaliplatin, cytarabine, and dexamethasone was added. The positron emission tomography scan performed as part of the baseline assessment (Figure 1, part 3) showed an abnormal uptake of the 18-fluorodeoxyglucose on the cardiac area. General tolerance of the chemotherapy was good, yet, the patient complained of palpitations 4 h after the end of the second course of treatment. Twelve-lead ECG showed a wide complex tachycardia, with left bundle branch block morphology with superior axis, atrioventricular dissociation, and fusion complexes consistent with ventricular tachycardia (VT) (Figure 1, part 1). This VT was well tolerated. It terminated spontaneously after 30 min. The ECG after the end of VT was normal. During the first 24 h of hospitalization, repetitive VT occurred (including non-sustained and sustained spontaneously terminating VT). The tolerance remained good. Morphological investigations showed that mediastinal lymphoma infiltrated the anterior wall of the right ventricle, as illustrated in Figure 1 (parts 2 and 3) and in Supplementary material online, Loop 1. The right ventricular free wall appeared thickened and infiltrated by a tumour that measured 10 × 5 cm. It was suspected that ventricular arrhythmias could be related to the tumour *per se*, or set off by tumour lysis after chemotherapy. Ventricular arrhythmias resumed after a loading dose of intravenous amiodarone (100 mg iv). It was followed by an association of oral amiodarone (loading dose of 800 mg then 200 mg daily) and nadolol (40 mg daily for 2 days then 80 mg daily). During each following sequence of chemotherapy, rhythm monitoring was performed in the ICU. There was no recurrence of sustained VT. Incidence of premature ventricular contractions decreased on Holter recordings. Five months later, a second morphological evaluation was performed after chemotherapy. Complete recovery of the right ventricular function was noted, without residual tumoural infiltration (Figure 1, part 3; see Supplementary material online, Loop 2). Considering the positive evolution, amiodarone was stopped. The patient remained asymptomatic for the next 11 months.

## Discussion

Cardiac involvement of mediastinum lymphoma is common and was reported in up to 75% of cases among patients with mediastinal lymphoplasmocytic lymphoma using echocardiography.<sup>1</sup> However, ventricular tachycardia seems to be rare. Only a few cases have been reported in the literature.<sup>2</sup> The current case illustrates the relationship between the regression of the tumoural mass under chemotherapy assessed by several imaging techniques and the resolution of the ventricular arrhythmias.

## Supplementary material

Supplementary material is available at *Europace* online.

**Conflict of interest:** none declared.

## References

- Meng Q, Lai H, Lima J, Tong W, Qian Y, Lai S. Echocardiographic and pathological characteristics of cardiac metastasis in patients with lymphoma. *Oncol Rep* 2002;**9**:85–8.
- Cho JG, Ahn YK, Cho SH, Lee JJ, Chung JJ, Park MR et al. A case of secondary myocardial lymphoma presenting with ventricular tachycardia. *J Korean Med Sci* 2002;**17**: 549–51.

## CASE REPORT

doi:10.1093/europace/euq129

Online publish-ahead-of-print 13 May 2010

# Type 1 electrocardiographic Brugada pattern in a woman with Chagas disease: a case report

Mitermayer R. Brito\*, Carlos Eduardo S. Miranda, Walter Rabelo, and Roberto L. Marino

Service of Cardiac Arrhythmias and Electrophysiology, Hospital Madre Teresa, Av Raja Gabaglia 1002 30380090 Belo Horizonte, MG, Brazil

\*Corresponding author. Tel/fax: +55 31 3296 6313, Email: miter@terra.com.br

A 56-year-old woman with well-documented Chagas disease was found to have a spontaneous type 1 electrocardiographic (ECG) pattern of Brugada syndrome. It is most likely that this characteristic ST-segment elevation is an unusual manifestation of the pathological changes in Chagas disease. This ECG pattern has been found with other cardiac pathology and has been reported to be induced in patients with Chagas disease.

## Case report

A 56-year-old woman with Chagas disease presented with syncopal episodes, sometimes preceded by palpitations. The diagnosis of Chagas disease was confirmed by positive immunofluorescence and haemagglutination tests to *Trypanosoma cruzi*. Her electrocardiogram (ECG) showed a spontaneous type 1 ECG pattern of the Brugada syndrome (BrS) (Figure 1) that was not related to anti-arrhythmic drug administration or febrile illness. This ECG pattern was not constant and sometimes reverted to a type 2